



# Beyond Breast Conservation

## Oncoplastic surgery in the community setting

**T**oday's cancer programs must be many things at once to their patients. They strive to be technologically up-to-date so their patients know they are receiving the safest, most precise procedures possible. While being sensitive to patients' personal needs, they must also draw on the most advanced thinking about diseases because our understanding of cancer is constantly evolving.

These factors are especially relevant to breast cancer patients, because the disease threatens not only a patient's future health but also body image, sense of well-being, and quality of life (QOL). Thus, for many patients, the challenge of treating breast cancer extends far beyond eradicating the disease and preventing a recurrence.

Central to our message: Cancer programs that do not currently have specialists who offer oncoplastic surgery to their breast cancer patients should consider learning more about these procedures and setting up a program to offer these services. To do so, cancer programs should also consider adopting new technologies to assist in the process.

### What Oncoplastic Surgery Offers

Oncoplastic surgery combines breast cancer surgery with plastic and reconstructive surgery techniques to make the cosmetic results of lumpectomy as pleasing and natural as possible. This surgery also encompasses nipple-sparing mastectomies with

Oncoplastic surgery is now becoming a better-known option at a time when there is increased focus on patient-centered care and shared decision-making.

reconstruction, although this article focuses largely on surgeries involving lumpectomy.

Rather than a specific group of techniques, oncoplastic surgery is, in part, a mindset about breast conservation (see "Getting It Right," page 43) that emphasizes not just cancer control but also cosmetic outcomes.

Oncoplastic surgery aims to achieve state-of-the-art cancer control while leaving patients with aesthetically pleasing cosmetic results that often hide the fact that they have had cancer surgery. Put another way, the advances that have made oncoplastic surgery possible mean that for many patients, it's no longer necessary to sacrifice a satisfying cosmetic outcome to get optimal cancer control.

---

Offering oncoplastic surgery demonstrates a commitment to delivery of cutting-edge, high-quality care. It is the only approach to breast conservation that combines cancer control, optimal cosmetic outcomes, and patient satisfaction.

---

Oncoplastic surgery builds on the benefits of conventional breast conservation treatment in which a lumpectomy is usually followed by radiation therapy and, when indicated, chemotherapy.

This article discusses the main considerations for a cancer program in offering oncoplastic surgery. We also examine the challenges that oncoplastic surgery presents for the radiation oncologist. These challenges arise because the tissue rearrangement occurring with oncoplastic surgery requires new approaches to locating, defining, and precisely irradiating the correct area of the breast.

### Patient Benefits

The efficacy of breast conservation treatment has now been demonstrated by multiple published long-term studies with at least 20-year follow-up results. The data show that this treatment matches mastectomy's overall survival rates<sup>2,3</sup> and in some scenarios has advantages over mastectomy.<sup>4</sup> But while breast conservation treatment has been shown to be equivalent to mastectomy in regards to cancer control, the cosmetic results for patients often fall short of the ideal, i.e., preservation of the appearance of a woman's breast as it looked prior to treatment. Lumpectomy surgery can often leave a patient with an indentation or divot in her breast. This occurs because cancerous tissue has been removed and the tissue deep in the breast has not been replaced or the area has been partially closed, without addressing gaps that might remain. Radiation therapy may then add to the cosmetic damage.<sup>5</sup> Research shows that roughly 30 percent of lumpectomies result in a deformity.<sup>6</sup>

Oncoplastic surgery is now becoming a better-known option at a time when there is increased focus on patient-centered care and shared decision-making. Today patients have greater access to information and education regarding breast cancer treatment options, along with quality of life considerations. Patients want their cancer cured, but they also want optimal cosmetic results following surgery. Oncoplastic surgery is the treatment option most in tune with a woman's desire to clear the breast cancer hurdle intact and enjoy a vital post-disease life.

### Programmatic Benefits

In addition to the patient benefits cited above, by adding oncoplastic surgery services, community cancer programs can demonstrate that they are:

- **Keeping up with the trend toward better cosmetic outcomes.** The trend is toward greater incorporation of oncoplastic surgery. The last five years or so have seen consistent growth in the approach. Oncoplastic surgery is clearly on the path to becoming a mainstream breast cancer treatment alternative.<sup>7</sup>
- **Responding to patient demands & interests.** Breast cancer patients may be well aware of the cutting-edge treatment options that are available today. Today's patients are often well informed through peer-to-peer networking, online discussion forums, and by high quality, forward-looking articles and other materials shared via online groups and through their own research efforts. Because oncoplastic surgery meshes with the hopes and desires of so many women, it is a popular topic among patients participating in online discussion forums. So community cancer programs should not be surprised when patients ask about oncoplastic surgery options.
- **Creating marketing & branding differentiators that are patient-centered.** Offering oncoplastic surgery demonstrates a commitment to delivery of cutting-edge, high-quality care. It is the only approach to breast conservation that combines cancer control, optimal cosmetic outcomes, and patient satisfaction. Cancer programs that provide oncoplastic surgery are responding to breast cancer patients' full range of concerns, thus offering patient-centered care.
- **Aligning with payer focus on value-based coordinated care.** Consistent with the goals of the Affordable Care Act (ACA), the Centers for Medicare & Medicaid Services (CMS) continues to develop payment models that reward "value and care coordination" as opposed to "volume and care duplication." Oncoplastic surgery is aligned with this incentive structure, providing optimal clinical and cosmetic value through well-coordinated care, while minimizing the chance of multiple surgeries that have related clinical risks and increased costs.
- **Providing an alternative option for patients inclined to undergo mastectomy.** There is a large cohort of breast cancer patients who are inclined to choose mastectomy today even though breast conservation treatment is an option for them. This cohort encompasses women whose post-surgical radiation therapy will possibly compromise their cosmetic outcome. Also included are women who hope to minimize the chance of local cancer recurrence. (Breast conservation treatment does present a slightly greater risk of local recurrence even though overall survival rates are comparable to mastectomy.)<sup>5</sup> In addition, this group includes breast conservation treatment candidates who want to avoid post-surgical radiation or chemotherapy.



Oncoplastic surgery can provide a better cosmetic outcome for many of the women in all of these subgroups. That's because skin-sparing (and sometimes nipple/areola-sparing) techniques can be employed without raising clinical risk.

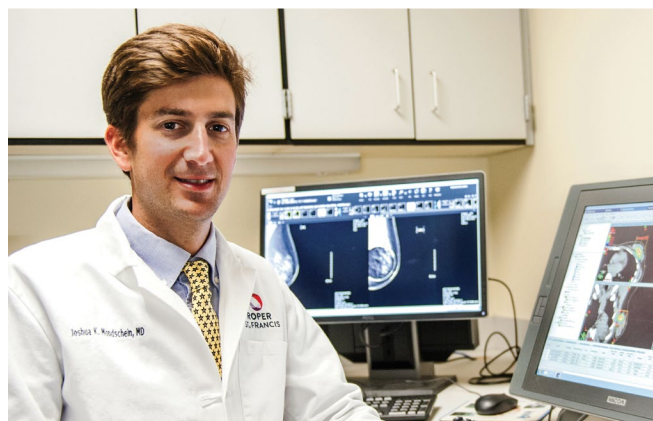
Some women may be considering mastectomy because they do not believe that the cosmetic outcomes of breast conservation treatment offer a good enough alternative. However, it's important to note that the cosmetic results of oncoplastic surgery improve upon standard breast conservation treatment. Indeed, a recent article in *The Breast Journal* reports that reconstruction of lumpectomy defects is often driven by women's concern about aesthetics and quality of life. The article further points out the need for training surgeons to expand the availability of oncoplastic surgery.<sup>8</sup>

Despite the logic that supports cancer programs offering oncoplastic surgery, the approach is not yet widely practiced by breast surgeons in the U.S. In part this is because oncoplastic surgery is not usually included as part of general surgeons' training or residency, although it is sometimes taught as part of a breast surgery fellowship. However, community cancer programs can take steps to develop a program offering oncoplastic surgery even if their breast surgeons are not currently proficient in the approach. Two possible pathways to offering oncoplastic surgery are:

1. A breast surgeon on the cancer program's staff can work in tandem with a plastic surgeon in the community or region, with the breast surgeon responsible for excising the tumor and the plastic surgeon performing the lumpectomy reconstruction.
2. A breast surgeon can receive training in oncoplastic surgery so that he or she can both excise the cancer and perform the lumpectomy reconstruction. It is important that the surgeon's instruction include hands-on training and not just lectures. Although there is no professional certification in oncoplastic surgery per se, it is taught in a number of forums across the country—from lectures to courses offered at some national conferences. For more on oncoplastic surgery training, see the box on page 44.

### Getting It Right: Ideal Dimensions of a Community-Based Oncoplastic Surgery Program

Oncoplastic surgery came into existence because of the growing importance of treating the “whole patient” and understanding patients' needs beyond the solely clinical. Patients who request oncoplastic surgery are likely to be women who want a holistic approach to care such that their opinions, desires, and emotions are respected in planning and executing their treatment. These patients also want to feel good about themselves in their post-treatment life, and they need their physicians to share that priority.



Paul Baron, MD, FACS (top), and Josh Mondschein, MD, MSCI.

Thus, an oncoplastic surgery program should be designed to reflect this “whole patient” approach, which may be somewhat different than the design of an exclusively clinical program. The holistic mindset of an oncoplastic surgery program applies comprehensively to all phases of the treatment process, including how the program is organized.

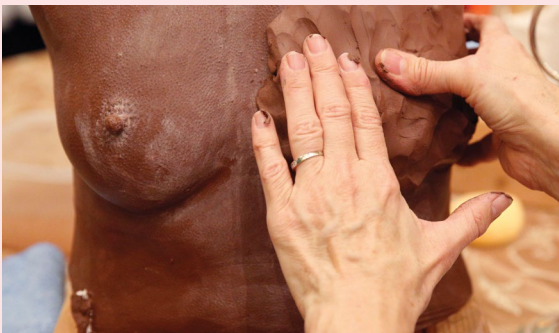Ideally, the various specialties involved in the patient's treatment—surgical oncology, radiology, plastic and reconstructive surgery, radiation oncology, and medical oncology—will function in a tightly integrated manner within the confines of the cancer program itself. But even if the oncoplastic surgery program pulls together various specialists affiliated with other entities in different locations or practice settings, it is important that each patient's case is comprehensively reviewed and discussed by all the specialists involved. This coordination can be accomplished via the tumor board or by detailed discussions between the breast surgeon and the other physicians involved in the care of the patient.

### More on Oncoplastic Surgery Training

In our opinion, lectures alone are insufficient in training for oncoplastic surgery because the confidence it takes for surgeons to competently perform procedures that are new to them comes from practicing them first. Currently, only a few of the courses available in this country include cadaver labs, where that practice takes place. While cadaver tissue is not as pliable as living tissue, the cadaver labs do provide valuable hands-on experience.

Courses offered by the American Society of Breast Surgeons ([breastsurgeons.org](http://breastsurgeons.org)), the School of Oncoplastic Surgery ([2016sos.com](http://2016sos.com)), and the American College of Surgeons ([facs.org](http://facs.org)) are among those that incorporate cadaver labs. The American Society of Breast Surgeons and American College of Surgeons courses are offered at the organizations' annual meetings. The School of Oncoplastic Surgery was founded by Gail Lebovic, MD, one of the pioneers of oncoplastic surgery.

Courses are also available internationally, especially in Europe, where oncoplastic surgery is practiced more widely than in the U.S. and where development of oncoplastic surgery began. For example, the Royal College of Surgeons of England ([rcseng.ac.uk](http://rcseng.ac.uk)) presents a course titled "Specialty Skills in Breast Surgery: Principles in Breast (Level 2)" that teaches oncoplastic and other reconstructive skills. The course includes a cadaver component. The Breast Surgeons of Australia and New Zealand organization ([rcseng.ac.uk](http://rcseng.ac.uk)) offers level 1 and 2 courses in oncoplastic surgery, with the level 2 course including a cadaver workshop.



At the School of Oncoplastic Surgery's sculpture lab, surgeon participants learn about the aesthetics of the breast while working with real-life clay models.

This type of coordination is important in part because the cosmetic aspects of oncoplastic surgery are based on the patient's own wishes. However, before the patient can make her choices, she needs to understand all her options and their implications. The best way to facilitate this shared-decision making process

During the preoperative evaluation, the patient should be asked about her cosmetic goals for surgery—i.e., what shape and size she would like her breasts to be when treatment is complete—and the implications of those choices should be discussed in full.

is to have all the specialists work together as a team and communicating to the patient in a mutually agreed-upon manner. This team approach is also good for the cancer program itself as it aligns with the reimbursement trend towards value-based, coordinated care.

### Preoperative Evaluation & Surgical Planning

Although most of the clinical details of an oncoplastic surgery program are beyond the scope of this article, here are a few important points on preoperative evaluation and surgical planning for oncoplastic surgery.

During the preoperative evaluation, the patient should be asked about her cosmetic goals for surgery—i.e., what shape and size she would like her breasts to be when treatment is complete—and the implications of those choices should be discussed in full. For instance, the patient's goals may require bilateral surgery to achieve the intended outcome. If the specifics of the tumor permit, the breast cancer surgery can be performed in tandem with a breast reduction, augmentation, or lift—if that is the patient's wish.

Surgical planning encompasses the choices that are made after a surgical path (breast conservation treatment or mastectomy) is chosen and the other steps in the preoperative evaluation are completed: the examination of prior records, a comprehensive medical history, the physical exam, imaging, and so on. Every part of the plan needs to combine clinical and cosmetic considerations.

At this point of the process, it may be determined that a lift, reduction, or augmentation is recommended to achieve breast symmetry, even if this step was not initially on the patient's wish list.<sup>9</sup> Patients with severe ptosis of the breast—that is, sagging, normally as a consequence of aging—may benefit from a lift, or mastopexy, as part of their breast cancer treatment. Women with macromastia (abnormally large breasts) may wish to include a breast reduction in their treatment plan once they better understand the details of how this would be accomplished. Lifts and reductions can be done either at the same time as a lumpectomy or as a second surgery after there is pathologic confirmation that the lumpectomy achieved clear margins. If a mastopexy is done as a second-stage procedure, the initial lumpectomy incision will be planned in such a way that it is included in the subsequent mastopexy incision.

Many times, the patient will just want the cancer removed and not want to go through the additional time and effort needed to improve breast symmetry or size. Usually these are older

patients. However, before a patient makes this decision, it's important for the breast surgeon to make sure that she fully understands the options available.

Incision placement is an important aspect of surgical planning. Oncoplastic surgeons seek to avoid leaving an unsightly scar. Even when a mastopexy is not involved, it helps, when feasible, to “hide” the incision in a location where it will not be visible—for example, along the inframammary fold. This can be done even when the tumor is located in a more central area of the breast.

Oncoplastic surgeons also aim to avoid a deformity caused by retraction, asymmetry, or a divot in the breast. Put another way, the surgical plan must include steps that ensure the breast will not look significantly different from the contralateral one. Normally, breast tissue that is adjacent to the surgical cavity will be advanced and sutured to partly fill the space, with the surgeon making adjustments as needed during the procedure to prevent any subsequent retraction.

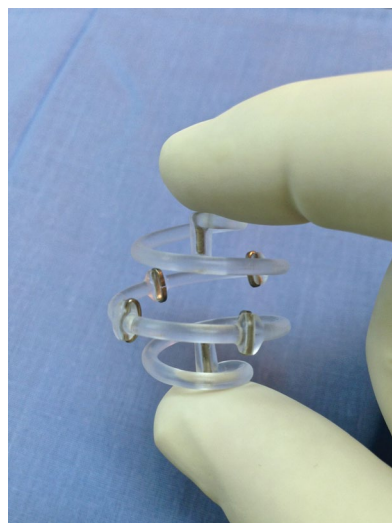Given the personalized and complex decision-making processes taking place during the preoperative evaluation and surgical planning stages, the need for tight coordination and communication between all physicians is clear. Most of these decisions involve many factors that must be considered simultaneously and they must be communicated to the patient sensitively in language she understands so that she can participate in the decision-making process. Thus, oncoplastic surgery is not only a new paradigm of breast cancer treatment, it also encompasses a new model for cooperation between medical disciplines that accords with evolving requirements from CMS and other payers.

### Oncoplastic Surgery & Post-Surgical Radiation Treatment

Oncoplastic surgery has downstream implications for the radiation oncologist because unlike the manner in which traditional breast conservation treatment is performed—where the tumor is simply removed and the surgical opening closed—oncoplastic surgery involves extensive tissue relocation and/or rearrangement. This makes it more challenging for the treatment planners and radiation oncologist to identify where the tumor was located and the area to be treated.

However, these challenges should be viewed in context. Precisely identifying the location of the tumor site can be problematic even with a traditional lumpectomy, i.e., without the tissue location factors of oncoplastic surgery. This is because the conventional marking methods, e.g., titanium clips and seroma, are notoriously unreliable, as is documented in the literature.<sup>10-12</sup> The clips can migrate and are merely marking the perimeter of the lumpectomy cavity; the tumor may have occupied an eccentric location in the space. Similarly, the seroma may only loosely correspond with the tumor-site location. As a result, treatment planners may inadvertently overestimate the treatment volume, resulting in excess radiation dosing of the patient.

Ideally, of course, the radiation oncology team wants to treat no more tissue than is necessary, to minimize the overall dose for the patient, and to avoid, if possible, irradiating adjacent healthy tissues and structures, such as the heart, skin, and lungs. At our



3D BioZorb device with titanium clips.

cancer program, we've found it helpful to use a new technology in conjunction with oncoplastic surgery—a small surgical implant (BioZorb, Focal Therapeutics/Aliso Viejo, Calif.), which is a marker that is sutured directly to the tumor site. This technology precisely delineates the tumor site, no matter how much tissue has been moved or removed, eliminating the issues created by tissue relocation and/or rearrangement.

The marker, which comes in multiple sizes and configurations to conform to breast size and/or clinical circumstances, has an open framework structure with six titanium clips in a fixed array. The framework is made of a bioabsorbable material that is slowly resorbed by the body over time—generally 12 to 18 months. The clips, which remain after the framework is resorbed, identify the tumor site in three dimensions.

Thus, the site can be clearly seen by radiation treatment planners for precise radiation treatment. The marker is also useful for contour radiation dosing, as well as more precise targeting of boost radiation. The implant's three-dimensional array of clips identifies the site for long-term follow-up imaging, too. Because the device is sutured to the site and the clips create a 3D image, there is little question about the precise location of the site, long after implantation of the device.

In our program, the BioZorb device has enhanced our surgical planning for oncoplastic surgery. Without the device, the radiation oncology team might be misled by the seroma created by the surgical tract and choose to irradiate a large area that includes the surgical tract, just to be on the safe side. The device eliminates that kind of overestimation because it is sutured to the tumor site. No matter where the surgical tract begins and ends, the radiation oncologist knows where to target the dose. This creates multiple cosmetic advantages, from incision location to more precise treatment.

The device also has another advantage for both breast conservation treatment and oncoplastic surgery. The framework fills up much of the space left behind by the tumor removal, so there is less chance of the divot that often occurs with ordinary lumpectomies. Eliminating the divot not only improves the cosmesis of the breast that was operated on but



also improves post-surgical breast symmetry. The device provides a scaffolding for the ingrowth of new tissue, as well. This helps account for the excellent cosmetic outcomes that have been reported by multiple users since the device was first introduced in 2012 and that we've seen with our patients at the Roper St. Francis Cancer Center. In many cases, the cosmetic result is so significant, that the mammography techs cannot find the locations of our incisions at the time of subsequent mammograms.

Finally, there are early indications that because it allows more precise radiation, the device may enable radiation oncologists to

employ a shorter course of radiation than usual with early breast cancer patients, reducing the normal six-week course to four weeks or less.<sup>13,14</sup> This shorter Canadian radiation protocol could open the way for more women to choose breast conservation treatment and oncoplastic surgery, because the pragmatic difficulties of arranging work and home schedules around a six-week radiation course can discourage some women from choosing breast conservation.

### Final Considerations

There are multiple reasons why community cancer programs should consider adding specialists who are familiar with onco-

### Oncoplastic Surgery: A Patient's Story

When J.H. was diagnosed with breast cancer in May 2015, her mind raced with fear—and a sense of inevitability. Her mother had died of late-stage breast cancer in 1999 at age 68, shortly after being diagnosed. The feeling that J.H.'s family history had caught up with her was reinforced a week later when her older sister was also found to have breast cancer. (J.H. and both of her sisters had previously taken the BRCA test, and the results were negative for all three women.)

Ever since her mother's diagnosis, J.H. had diligently undergone annual mammograms. Because of that diligence J.H.'s cancer was detected at an early stage and that turned out to make a big difference in her treatment options. J.H., who is married with two grown children, lives in Mount Pleasant, S.C., near Charleston. Her breast surgeon and radiation oncologist for her treatment were the Charleston-based authors of this article, Paul Baron, MD, FACS, and Josh Mondschein, MD. Dr. Baron told J.H. that her prognosis was favorable because she had stage 1 disease and it was growing slowly. She briefly considered getting a mastectomy but after further discussion with Dr. Baron, decided to have oncoplastic surgery instead.

Dr. Baron performed J.H.'s cancer excision. During the surgery, he sutured a 3D bioabsorbable marker (discussed on page 45) to the tumor site. The marker was placed to serve several purposes. On the surgical side, it supported the cosmetic goals of the oncoplastic approach by filling the space left by the lumpectomy and providing a scaffolding for tissue ingrowth. The marker placement also made it possible for Dr. Mondschein to target the post-surgical radiation treatments more accurately because the tumor site was marked clearly in three dimensions. J.H. was able to receive a short, four-week course of radiation therapy because her tumor was low-risk and met specific criteria outlined by the American Society for Radiation Oncology (ASTRO).




J.H. was pleased and surprised at how quick and efficient her radiation treatment was. She felt good throughout the process, so she was able to keep up her exercise regimens of walking, biking, and swimming. She also felt energetic enough to continue her work as an office manager for a private school, which she fit in around the treatment schedule. The fact that her treatment had so little impact on her daily life helped her stay optimistic about the eventual outcome. She called the treatment “a piece of cake.”

J.H. is confident that the decision to have oncoplastic surgery and radiation treatment instead of a mastectomy was the right one. She's also pleased that using the 3D marker improved the radiation treatment planning and targeting, which protected her healthy tissue from radiation exposure. She has no visible scar, wears the same size bra as before her diagnosis, and can't see or feel the marker. She says, “If you didn't know I'd had breast cancer, you wouldn't be able to tell.”

plastic surgery to their breast cancer services if they haven't already done so. Those reasons start with the fact that no cancer program can remain competitive unless it offers state-of-the-art treatment of the highest quality. With respect to breast cancer, that means offering oncoplastic surgery, which provides improved cosmetic outcomes without comprising cancer control. That said, cancer programs should understand all that is implied by the term oncoplastic surgery. It is a mindset about breast cancer surgery in addition to a method and technique. To provide oncoplastic surgery is to consider the cosmetic outcome at every stage of the treatment process, starting with the preoperative evaluation and surgical planning and continuing through the post-operative radiation treatment. Every one of these stages can affect the eventual cosmetic results so the oncoplastic surgery mindset must guide every decision made throughout the chain of events that comprise the total treatment process. The holistic, comprehensive nature of oncoplastic surgery should be reflected in the way the oncoplastic surgery program is organized, as well. The end goal of treatment is determined by the patient's desires as she expresses them to her doctors. So the cancer program must foster excellent communication between the patient and all the medical specialists involved, as well as between the specialists themselves.

As mentioned above, oncoplastic surgery programs vary in how the actual surgery is accomplished. A breast surgeon can work in tandem with a plastic surgeon to achieve the optimal results. Alternatively, a breast surgeon can receive advanced training in oncoplastic surgery and perform both the excision and the reconstruction. The first configuration is an excellent way for a cancer program to begin its oncoplastic surgery program. As the program develops, the breast surgeon may then want to train in oncoplastic surgery and eliminate the need for a plastic surgeon to be involved in many of the surgical cases. As an example, the co-author of this article, Dr. Paul Baron, performs most of the oncoplastic surgery on his patients. However, he works in tandem with a plastic surgeon in those cases undergoing mastopexies (breast lifts) and reductions following breast conservation treatment, and reconstructions following skin or nipple-sparing mastectomies.

While oncoplastic surgery has the reputation in some quarters of making post-operative radiation treatment planning challenging, we have found that use of new technology (the innovative 3D marker described above), overcomes the imprecision issue with both breast conservation treatment and oncoplastic surgery, while also providing other advantages that may improve cosmetic outcomes. Accordingly, we suggest that this technology be considered in conjunction with an oncoplastic surgery program and for patients receiving breast conservation treatment. 

*Paul Baron, MD, FACS, is a board certified general surgeon for Roper St. Francis Physician Partners in Charleston, S.C. who completed a Fellowship in Surgical Oncology at Memorial Sloan Kettering Cancer Center, and is a clinical associate professor of Surgery at the Medical University of South Carolina. He is a*

*Fellow of the American College of Surgeons and the Society of Surgical Oncology and an active member of the American Society of Breast Surgeons. Josh Mondschein, MD, MSCI, is a board certified radiation oncologist at Roper St. Francis Healthcare in Charleston, S.C. who completed a residency in Radiation Oncology at Vanderbilt University, and is a clinical assistant professor of Radiation Oncology at the Medical University of South Carolina.*

## References

1. Lebovic GS. Oncoplastic surgery: blending science and art. In: Urban C, Rietjens M, eds. *Oncoplastic and Reconstructive Breast Surgery*. Milano, Italy. Springer-Verlag Italia; 2013:3-11.
2. Fisher B, Anderson S, Bryant J, et al. Twenty-year follow-up of a randomized trial comparing total mastectomy, lumpectomy, and lumpectomy plus irradiation for the treatment of invasive breast cancer. *N Engl J Med*. 2002;347:1233-1241.
3. Veronesi U, Cascinelli N, Mariani L, et al. Twenty-year follow-up of a randomized study comparing breast-conserving surgery with radical mastectomy for early breast cancer. *N Engl J Med*. 2002;347:1227-1232.
4. Agarwal S, Pappas L, Neumayer L, et al. Effect of breast conservation therapy vs mastectomy on disease-specific survival for early-stage breast cancer. *JAMA Surg*. 2014;149(3):267-274.
5. Lebovic GS. Oncoplastic surgery: a creative approach to breast cancer management. *Surg Oncol Clin N Am*. 2010;19(3):567-580.
6. Grotting JC, Neligan PC. *Plastic Surgery: Volume 5: Breast*. 3rd ed. Philadelphia, Penn. Saunders; 2012:586.
7. Carmichael AR, Mokbel K. Evolving trends in breast surgery: oncoplastic to onco-aesthetic surgery. *Arch Plast Surg*. 2016;43(2):222-223.
8. Losken A, Kapadia S, Egro FM, et al. Current opinion on the oncoplastic approach in the USA. *Breast J*. 2016;Apr 9. [Epub ahead of print].
9. Lebovic GS, Anderson BO. Oncoplastic breast surgery: current status and best candidates for treatment. *Curr Breast Cancer Rep*. 2009;1(2):118-123.
10. Landis DM, Luo W, Song J, et al. Variability among breast radiation oncologists in delineation of the postsurgical lumpectomy cavity. *Int J Radiat Oncol Biol Phys*. 2007;67:1299-1308.
11. Machtay M, Lanciano R, Hoffman J, Hanks GE. Inaccuracies in using the lumpectomy scar for planning electron boosts in primary breast carcinoma. *Int J Radiat Oncol Biol Phys*. 1994;30:43-48.
12. Hepel J, Evans S, Hiatt JR, et al. Planning the breast boost: comparison of three techniques and evolution of tumor bed during treatment. *Int J Radiat Oncol Biol Phys*. 2009;74:458-463.
13. Harman J, Govender S, Benjamin B, Simpson J. An improved method for marking the surgical cavity during partial mastectomy. Poster presentation available at: [focalrx.com/wp-content/uploads/2014/01/FMRK-11-04\\_Rev-A\\_Poster-Handout\\_RANZCR-2013\\_PRINTABLE.pdf](http://focalrx.com/wp-content/uploads/2014/01/FMRK-11-04_Rev-A_Poster-Handout_RANZCR-2013_PRINTABLE.pdf). Accessed June 9, 2016.
14. Cross M, Ross J, Jones S, et al. Identifying the surgical cavity after oncoplastic breast surgery. Poster presentation available at: [focalrx.com/wp-content/uploads/2014/01/FMRK-11-07\\_Rev-A\\_Poster-Handout\\_ASCO-Breast-2014\\_PRINTABLE.pdf](http://focalrx.com/wp-content/uploads/2014/01/FMRK-11-07_Rev-A_Poster-Handout_ASCO-Breast-2014_PRINTABLE.pdf). Accessed June 9, 2016.